



A Rare Presentation of Prostatic Adenocarcinoma Metastasized to the Occipito-Parietal Bones

Oksipito-Paryetal Kemik Metastazı Olan Nadir Prostat Adenokarsinom Olgusu

Prostat Adenokarsinom Metastaz Olgusu / A Presentation of Prostatic AdenoCA Metastases

Emrah Okulu, Kemal Ener, Mustafa Aldemir, Murat Keske, Onder Kayigil
The Urology Clinics of Ankara Atatürk Training and Research Hospital, Ankara, Turkey

Özet

Prostat kanserinin kemiğe metastaz eğilimi oldukça yüksek olmakla beraber sıklıkla aksiyel iskelet sisteminde meydana gelmektedir ve morbidite ve mortaliteye yol açmaktadır. Biz oksipito-paryetal kemik metastazı olan prostat adenokarsinom olgusunu sunuyoruz. Kemik dışında beyin de prostat adenokarsinomun sık görülen metastazıdır ancak oksipito-parietal kafa kemiği metastazı oldukça nadir görülmektedir. Bu vaka hiçbir semptom ve bulgu vermeden sadece oksipito-paryetal kafa kemiği tutulumu ile seyreden nadir bir prostat adenokarsinom olgusu olmasından dolayı, literatürdeki ilk olgulardan birisidir.

Anahtar Kelimeler

Prostat Adenokarsinom; Oksipito-Paryetal Kemik; Kafatası Metastazı

Abstract

Prostate adenocarcinoma has a strong tendency to metastasize to bone, particularly axial skeleton occurs at high frequency in patients with that causing significant morbidity and mortality especially. We present a rare case of prostatic adenocarcinoma having metastatic occipito-parietal bone involvement. Apart from bone, brain is also a common site of metastasis but the involvement of the occipito-parietal bone is extremely unusual. Occipito-parietal bone metastasis from prostatic adenocarcinoma was the initial presentation which was observed in our patient. This is the first case of its kind in the literature where the prostatic carcinoma had metastasized to the occipito-parietal bone of the skull without any symptomatology of prostatic adenocancer involvement.

Keywords

Prostate Adenocancer; Occipito-Parietal Bone; Skull Metastasis

DOI: 10.4328/JCAM.1136

Received: 06.06.2012 Accepted: 25.06.2012 Printed: 01.07.2015

J Clin Anal Med 2015;6(4): 531-3

Corresponding Author: Emrah Okulu, Umit Mh. Meksika Cd. 2463. Sk. 4/32 Umitkoy, Yenimahalle, Ankara, Turkey.

T.: +90 3122354914 F.: +90 3122912705 E-Mail: eokulu@yahoo.com

Introduction

Prostatic adenocarcinoma has a strong tendency to metastasize to bone particularly axial skeletal bone and less commonly to the cranium. However, occipito-parietal bone involvement is rare. Skull metastasis must be kept in mind when considering the differential diagnosis of a skull tumor [1]. Most metastatic skull lesions are asymptomatic, but they can cause severe disability due to compression of dural sinuses and cranial nerves [2]. Skull metastases are rarely diagnosed clinically, but are frequently found in autopsies [2]. Despite the fact that hematogenous skull metastases can derive from nearly all types of tumors, breast cancer is associated with the highest rate of metastatic skull lesions. This is the first case of its kind in the literature where the prostatic carcinoma had metastasized to the occipito-parietal bone of the skull without any symptomatology of prostatic adenocancer involvement. We present a rare case of prostatic adenocarcinoma presenting with metastatic occipito-parietal bone involvement.

Case Report

A 75-year-old man presented with only isolated serum prostate-specific antigen (PSA) elevation to our clinic. There was a history of hyperlipidemia, diabetes mellitus and cholecystectomy operation. Physical examination was unremarkable. The patient denied any urinary symptoms. Serum total PSA measured before digital rectal examination (DRE) was 23.13 ng/ml. Basic laboratory examinations of complete blood count, serum biochemistry, and urine analysis were normal except cholesterol and glucose levels. DRE revealed an enlarged, firm prostate gland. Transrectal ultrasound guided prostate needle biopsy was performed in this patient. The pathological examination revealed adenocarcinoma of the prostate (Gleason 4+4). Abdominal computed tomography (CT) scan and whole-body bone scintigraphy were performed in this patient. Abdominal CT scan revealed heterogeneous parenchymal density of the prostate and the other structures were normal. Bone scintigraphy revealed occipito-parietal bone metastases (Figure 1). There

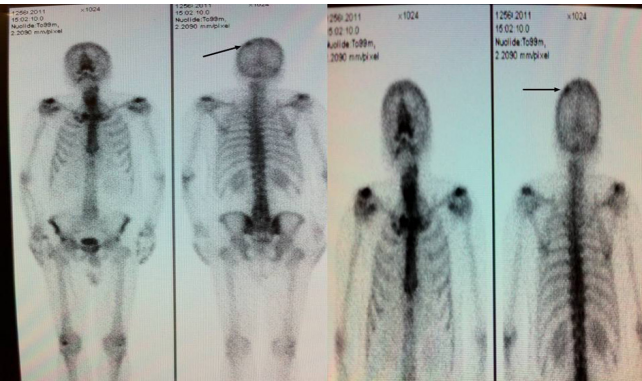

Figure 1. Bone scan demonstrates occipito-parietal bone metastases.

was no history of trauma in our patient. After bone scintigraphy, magnetic resonance imaging (MRI) was performed and revealed 17 mm osteolytic metastatic mass in occipito-parietal bone (Figure 2). LHRH agonist and bicalutamide treatment was started for this patient. Serum PSA decreased below 1.09 ng/ml with in 3 months. The patient had no evidence of PSA biochemical failure have not reappeared for 6 months. His serum PSA

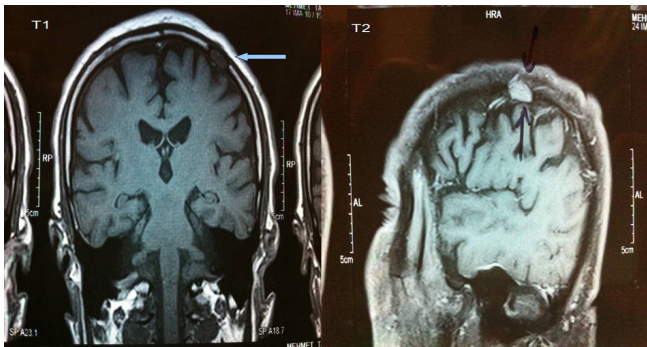


Figure 2. T1 hypointense and T2 weighted image hyperintense demonstrating contrast enhancement occipito-parietal metastatic mass.

measured was 0.069 ng/ml at 6 months follow-up and occipito-parietal bone metastatic lesion was an improvement in MRI at 6 months follow-up.

Discussion

Patients with skull metastases were characterized by higher age, shorter duration of symptoms, and less frequently presented with neurological deficit, when compared to primary skull tumors and benign tumor-like lesions [3]. Despite the fact that breast cancer is associated with the highest rate of metastatic skull lesions, nearly all types of tumors (lung, prostate, thyroid carcinoma, malignant melanoma) can cause hematogenous skull metastases [3]. Skull metastases cause local swelling that is usually painless, and rarely they lead to neurological dysfunction. The differential diagnosis of metastasis should always be considered when a lytic skull lesion is identified. Multiplicity, irregular edges, and absence of peripheral sclerosis should arouse suspicion of malignancy [8]. Surgical excision cannot influence the underlying disease but can be achieved with low morbidity, and the mean survival time after the development of a skull metastasis is approximately 20 months [3]. Paget disease and multiple myeloma were excluded, because the patient with primary diagnosis of prostate adenocarcinoma has only one skull lesion which shows osteoblastic activity. In addition, there is no history of trauma in a patient.

Prostatic adenocarcinoma tends to spread to the axial bony skeleton and rarely to the cranium. The most common sites are the spine, sacrum and pelvis. Occipito-parietal metastases caused by prostate cancer are rare. It is not unusual in these sites for the bone metastases to become symptomatic before there is any recognition of the primary lesion [4]. There are a few reported skull metastatic cases. The other study reported a case of metastatic prostatic adenocarcinoma presenting with parietal bone involvement [5] and other study reported two cases with temporal bone involvement [6]. Occipito-parietal bone metastases of prostate adenocancer have not been reported in the literature before. In our patient is the first case of its kind in the literature where the prostatic carcinoma had metastasized to the occipito-parietal bone of the skull without any symptomatology of prostatic adenocancer involvement.

The prognosis of these patients seems to depend on the effectiveness of hormonal treatment [3]. Most cases of metastatic prostatic adenocarcinoma can be controlled with hormone therapy, either by the means of surgical castration or medically with the use of LHRH analogues. Response rates are around 85%

with a median time to progression of 18–24 months before becoming hormone-refractory [7].

In conclusion, awareness that metastatic prostatic adenocarcinoma may present with occipito-parietal bones involvement and without any symptomatology should lead the clinician to re-view the radiological appearance. Our case is intended to alert the reader of this rare site of metastasis from the prostate.

Acknowledgement

“This manuscript has been revised for language mistakes by a native speaker and professional medical editor of English (Safak Ugur, PhD English and American Literature- Writing Academic English-Middle East Technical University-Modern Languages dept.) for 17 years’

Competing interests

The authors declare that they have no competing interests.

References

1. Bontoux D, Plazanet F, Azais I. Distribution of bone metastases of cancers. A scintigraphic study of 376 cases. Bull Acad Natl Med 1998;182(5):997-1008.
2. Gloria Cruz TI, Schachern PA, Paparella MM, Adams GL, Fulton SE. Metastases to temporal bones from primary nonsystemic malignant neoplasms. Arch Otolaryngol Head Neck Surg 2000;126(2):209-14.
3. Stark AM, Eichmann T, Mehdorn HM. Skull metastases: clinical features, differential diagnosis and review of the literature. Surg Neurol 2003;60(3):219-26.
4. Saito H, Hida M, Shimbo T, Nakamura K, Yamagata J, Satoh T. Metastatic patterns of prostatic cancer. Correlation between sites and number of organs involved. Cancer 1984;54(12):3078-84.
5. Khan R, Maheshwari V, Harris SH, Alam K. Prostatic adenocarcinoma metastasizing to the parietal bones. Ind J Pathol Microbiol 2007;50(4):759-61.
6. Sahin AA, Ro JY, Ordonez NG, Luna MA, Weber RS, Ayala AG. Temporal bone involvement by prostatic adenocarcinoma: report of two cases and review of the literature. Head Neck 1991;13(4):349-54.
7. Catalona WJ. Management of cancer of the prostate. N Engl J Med 1994;331(15):996-1004.
8. Wong GK, Boet R, Poon WS, Ng HK. Lytic skull metastasis secondary to thyroid carcinoma in an adolescent. Hong Kong Med J 2002;8(2):149-51.

How to cite this article:

Okulu E, Ener K, Aldemir M, Keske M, Kayigil Ö. A Rare Presentation of Prostatic Adenocarcinoma Metastasized to the Occipito-Parietal Bones. J Clin Anal Med 2015;6(4): 531-3.